

# Intractable Pain Therapy Using a New Epidural Catheter

Gabor B. Racz, MD; Magdy Sabonghy, MD; Jonas Gintautas, MD, PhD; William M. Kline

• Conventional epidural catheters used in performing neurolytic blocks create frequent problems such as kinking, misplacement, and questionable localization of the catheter. We present a study of a new epidural catheter for injection of phenol in patients with severe pain problems. In four of five cases complete pain relief was obtained for several months. The design of this catheter provides improved localization of the injection site.

(JAMA 1982;248:579-581)

INTRATHECAL injections of phenol for the control of cancer pain was introduced in 1955.<sup>1</sup> Possible complications using this technique include spread of the neurolytic agent to larger areas than desired, meningitis, arachnoiditis, muscular weakness, bladder weakness, urinary incontinence, headache, bowel incontinence, paresthesias, and thrombosis of spinal arteries causing extensive necrosis of the spinal cord.<sup>2,3</sup>

Epidural injection of phenol using conventional catheters does not appear to have major complications. However, determination of the exact location of the tip of the catheter during injection and kinking of the catheter remain as major problems.<sup>4,5</sup> One method for verification of correct placement of a Teflon-type epidural catheter is the injection of a radiopaque material followed by x-ray filming of the area.<sup>1</sup> However, the films may not show the exact position of the catheter tip. Aspiration for CSF or blood through regular plastic catheters may miss the subarachnoid or intravascular placement. There are several reports<sup>6,7</sup> indicating frequent problems in kinking, misplacement, and difficulties in localizing the catheter, thus leading to undesirable injection sites. Therefore, our purpose is to report on a new type of epidural catheter in pain control.

A new epidural catheter made of spiral stainless steel coils coated with

fluoropolymers (Fig 1) has been successfully used by our group for anesthesia or analgesia purposes with more than 100 patients. Recently we began using the catheter in pain therapy.

## Materials and Methods

Five patients described herein were seen in our pain center with chronic, intractable thoracic pain. All patients were hospitalized. Three patients had invasive carcinoma of the lung, one patient had posttraumatic brachial plexus injury and shoulder pain, and one patient had chronic postherpetic neuralgia. Informed consent was obtained. The procedure was conducted in the pain center, which is equipped with ECG monitor and life support systems. Vital signs of the patients were monitored, an intravenous route was established, and sedation was used as needed. The patients were placed in a slightly head-up position with the painful area in a dependent position. The catheter was placed at the level of the involved segment via an 18-gauge Hustead tip epidural needle. The appropriate extradural, segmental location was identified using a midline approach, loss of resistance method, and x-ray films.<sup>8</sup> Effects of the placement were further tested using a local anesthetic (3 to 4 mL of 0.5% bupivacaine hydrochloride). The catheter was left in place, and the following day, 3 to 4 mL of 6% phenol in saline in 0.5-mL increments was injected. The patients were kept in the same position at least for one hour to allow fixation of the neurolysis. The catheter was removed one day after satisfactory pain relief was obtained and inspected for mechanical or chemical damage. There was no evidence of chemical interaction between the catheter wall and phenol in any of the catheters used.

## Report of Cases

CASE 1.—A 61-year-old man had intolerable pain in the right shoulder, right




Fig 1.—Comparison of sizes: A, epidural catheter. Tip of catheter and extended spiral stainless steel coils of injection area are displayed. Longitudinal supportive metal core is inside the catheter. White surface is a coat of fluoropolymers. B, 18-gauge Hustead tip epidural needle. Scale: 1 mm between black bars on top of photograph.

upper arm, and right upper thorax caused by invasive adenocarcinoma of the upper lobe of the right lung. The patient had previously undergone right upper and middle lobectomy after radiation therapy; subsequently, muscular wasting of the area and Horner's syndrome were noted. Repeated right stellate ganglion blocks gave partial temporary pain relief. Upper thoracic epidural block, as described previously, with placement of the catheter tip at the seventh cervical level and an injection with 3 mL of 6% phenol in saline resulted in complete pain relief for four months, without additional neurological deficit.

CASE 2.—A 61-year-old woman had a two-year history of inoperable adenocarcinoma of the upper lobe of the left lung that had been treated by radiation therapy. For her intractable pain, she received large doses of meperidine hydrochloride, chlorpromazine, and hydromorphone hydrochloride. She came to our pain center complaining of continuous pain in the upper chest and left arm. A lower cervical

From the Department of Anesthesiology, Texas Tech University Health Sciences Center, Lubbock (Drs Racz, Sabonghy, and Gintautas); and the Medical Evaluation Devices and Instruments Co, Gloversville, NY (Mr Kline). Dr Sabonghy is currently in private practice in Albuquerque.

Reprint requests to Department of Anesthesiology, Texas Tech Health Sciences Center, Lubbock, TX 79430 (Dr Racz).

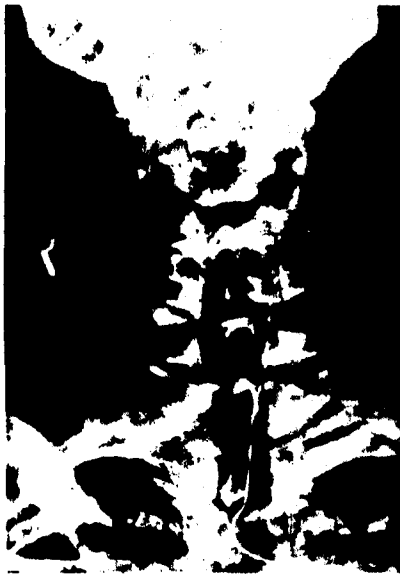

Fig 2.—Roentgenogram showing localization of catheter in cervical (C-6) region (case 2).

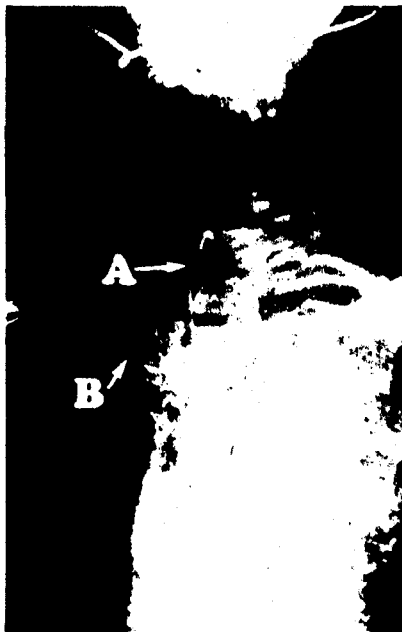


Fig 3.—Position of catheter at upper thoracic (T-1) level (case 3). A indicates tip of catheter, B, body of catheter.

(sixth cervical level) epidural block with 0.5% bupivacaine hydrochloride was performed. The following day, 3 mL of 6% phenol in saline was injected using the new epidural catheter. Position of the catheter and tip was determined by x-ray films (Fig 2). The result was complete pain relief.

She was discharged from the hospital pain free, after having the drug therapy terminated. Three months later the patient was still free of pain.

**CASE 3.**—A 32-year-old man complained of pain in the left upper thorax, left

shoulder, and left upper arm with muscle weakness in the upper arm resulting from a fall from an offshore oil rig, in which he landed on his left shoulder and chest. The accident occurred two years before he came to the pain center. The patient was receiving the following intramuscular medications: meperidine hydrochloride, 75 mg, and promethazine hydrochloride, 50 mg every two hours. An upper thoracic (first thoracic level) epidural block was performed, first with 4 mL of 0.5% bupivacaine hydrochloride followed by injection of 4 mL of 6% phenol in saline. Complete pain relief lasted eight months, and no narcotics were required during that time. The patient returned and requested a second block. Immediately after his second phenol block, there was numbness involving the opposite hand; however, sensation returned after ten days. No other neurological defect appeared. The position of the catheter is illustrated in Fig 3. The second injection of phenol gave four months of pain relief.

**CASE 4.**—A 49-year-old man had chronic postherpetic neuralgia at the fourth, fifth, and sixth thoracic level on the left side.

After a series of intercostal and paravertebral blocks with local anesthetics and phenol, the patient still complained of pain. The epidural catheter tip was placed at the upper thoracic vertebra (fourth thoracic level), and 4 mL of 0.5% bupivacaine hydrochloride was injected, which resulted in good pain relief. The next day, 4 mL of 6% phenol in saline was injected. The patient experienced excellent pain relief; however, the pain returned after two weeks. A decision was made to use surgical intervention with intercostal neurectomies. Postoperatively there was no pain relief. The patient's condition is controlled with narcotics.

**CASE 5.**—A 54-year-old man had carcinoma of the right lung and brain metastases. His major complaint was severe pain in the right shoulder, upper arm, and right upper thorax. The patient, before admission, received radiation therapy, chemotherapy, and narcotics. After confirmation by x-ray films that the location of the epidural catheter was at the seventh cervical vertebra, 3 mL of 0.5% bupivacaine hydrochloride gave good pain relief. The next day, 3 mL of 6% phenol in saline solution was injected. The patient was completely free of pain three months after injection.

#### Comment

The major complaint of most patients with cancer is pain. The different ways to alleviate pain are (1) pain medication, (2) surgical interventions, and (3) neurolytic blocks using alcohol or phenol. Alcohol has a high incidence of postinjection neuro-

toxicity. The main disadvantages of the pain medication (narcotics) are drug abuse, addiction, hallucination, drug tolerance problems, drowsiness, and incomplete relief. The disadvantage of surgical procedures is that major surgery carries extra hazards in poor-risk patients. Thus, neurolytic blocks have been used for the last two decades and offer good pain relief but also bring major risks, especially if the pain is in the upper part of the body.<sup>1</sup>

Identification of the epidural space in the cervical and high thoracic areas is not a particularly great problem in experienced hands; however, the hazard of inadvertent subarachnoid or intravascular injection is ever present if injection is done through a sharp needle in the narrow epidural space.

A new epidural catheter has been developed that allows precise deposition of local anesthetics first, followed by neurolytic phenol injection. The catheter is constructed of surgical-grade stainless steel spiral coils with a blunt tip and open spiral loops near the tip for injection. The rest of the length of the catheter is dip-coated plastic as an integral part of the wall. Within the lumen from one end to the other, a safety wire is welded in place, at both ends (Fig 1). The catheter passes through an 18-gauge, thin-wall epidural needle and because of the wall construction has good flow characteristics. The tip of the catheter can be located exactly by x-ray films and may be repositioned as required for accuracy. In the event of subarachnoid placement with the new catheter, CSF will be quickly visible even without aspiration, however, aspiration is recommended for safety. High thoracic or cervical subarachnoid injections of 3 to 4 mL of 0.5% bupivacaine hydrochloride would result in a major spinal block within two to three minutes, whereas the same dose in the epidural space will block two to four segments in ten to 15 minutes. The onset of action is much slower and mainly sensory, which further confirms epidural placement of the catheter.

The patient described in case 3 had excellent pain relief for eight months. At the recurrence of pain, the patient requested a repeated injection that was done with equally good results.

The three patients with pulmonary

invasive cancer had total pain relief, allowing withdrawal of narcotics during a five-day period by substitution with decreasing doses of methadone hydrochloride. All three patients are pain free and are presently not taking narcotics.

The fourth patient had two weeks of pain relief and elected to undergo an intercostal neurectomy that again failed. The patient has returned to taking narcotics for pain relief. Post-herpetic neuralgia pain, particularly when it becomes chronic, does appear to have a central component that does not respond to peripheral interruption of pain pathways."

We conclude that the epidural catheter described allows accurate and

easily verifiable placement of phenol and may successfully be used in control of intractable pain, particularly in patients with cancer.

The catheter was designed by William M. Kline, Ronald R. Rizzo, and Mark E. Orlosky, Medical Evaluation Devices and Instruments Co, Gloversville, NY, and was evaluated in the Anesthesiology Research Laboratories, Texas Tech University Health Science Center, Lubbock.

Belinda Brice, RN, coordinator of the pain center, has been most helpful in the care of these patients.

#### References

1. Maher RM: Relief of pain in incurable cancer. *Lancet* 1955;1:16-19.
2. Wood KM: The use of phenol as a neurolytic agent: A review. *Pain* 1979;5:205-229.
3. Totoki T, Kato T, Nomoto Y, et al: Anterior spinal artery syndrome: A complication of cervi-

cal intrathecal phenol injection. *Pain* 1979;6:96-104.

4. Kaufman RD, Reynolds RC: Occlusion of an epidural catheter secondary to osteoarthritis. *Anesthesiology* 1976;44:253-255.

5. Browne RA, Politi VL: Knotting of an epidural catheter: A case report. *Can Anaesth Soc J* 1979;26:142-143.

6. Ward CF, Osborne R, Renumof JL, et al: A hazard of double-orifice epidural catheters. *Anesthesiology* 1978;48:362-364.

7. Shiau HF, Hwang HS, Marx GF: Prevention of external kinking of extradural catheter. *Anesth Analg* 1977;56:865-866.

8. Shuman RL, Peters RM: Epidural anesthesia following thoracotomy in patients with chronic obstructive airway disease. *J Thor Cardiovasc Surg* 1976;71:82-88.

9. Blass NH, Roberts RB, Wiley JK: The case of the errant epidural catheter. *Anesthesiology* 1981;54:419-421.

10. Bromage PR: *Epidural Analgesia*. Philadelphia, WB Saunders Co, 1978.

11. Kernbaums S, Hauchecorne J: Administration of levodopa for relief of herpes zoster pain. *JAMA* 1981;246:132-134.